

# Aplastic anemia and pregnancy – a case report

© GinPolMedProject 4 (38) 2015

Case report

MAJA KUFELNICKA-BABOUT<sup>1</sup>, ANNA SZMIGIELSKA-KAPŁON<sup>2</sup>, JAROSŁAW KALINKA<sup>1</sup>

<sup>1</sup> Klinika Perinatologii Uniwersytetu Medycznego w Łodzi,  
Kierownik: prof. dr hab. n med. Jarosław Kalinka

<sup>2</sup> Klinika Hematologii Uniwersytetu Medycznego w Łodzi  
Kierownik: prof. dr hab. med. Tadeusz Robak

Address for correspondence:

Jarosław Kalinka

Klinika Perinatologii Uniwersytetu Medycznego w Łodzi

ul. Wileńska 37, 94 029, Łódź

Tel +48 42 68 04 620, fax +48 42 68 68 209, e-mail: mkufel2000@yahoo.fr,  
j.kalinka@csk.am.lodz.pl, anna.szmigielska-kaplon@umed.lodz.pl

## Statistic

Word count	2240
Tables	1
Figures	3
References	15
Received:	19.05.2015
Accepted:	27.07.2015
Published:	21.12.2015

## Summary

Aplastic anemia is a rare serious disease (2–6 cases/1 million/year), which can be diagnosed also in pregnant women. In the blood count, anemia, thrombocytopenia and leukopenia are present. The symptoms of hemorrhagic diathesis and the tendency to infection with a serious outcome is usually observed. The management of a patient with aplastic anemia during pregnancy requires close cooperation between obstetricians and hematologists. Due to the increased risk of hemorrhage and infections during pregnancy, delivery and post-partum period, there is a significant risk of demise for both the mother and her child.

The article presents the case of a 29-year-old patient with pancytopenia (first detected after 14 weeks of gestation) and subsequent aplastic anemia.

**Key words:** aplastic anemia; pregnancy; perinatal hemorrhage

## INTRODUCTION

Aplastic anemia (AA) is characterized by the deficiency of all blood cell types in the peripheral blood and hypoplasia or aplasia of hematopoietic cells in the bone marrow without the presence of cells pathological for the bone marrow [1–4]. In adults, AA is usually idiopathic and associated with the autoimmunization process (1–4). The secondary form of AA, induced by myelotoxic agents, such as chemicals (organic solvents, herbicidal or insecticidal agents and certain drugs, e.g. cyclophosphamide, metamizole, sulfonamides or methotrexate), must always be ruled out. Bone marrow aplasia can also accompany viral infections, mainly hepatitis B and C.

Aplastic anemia is a rare disease with the incidence of 2–6 cases per 1 million people. Its idiopathic form is usually diagnosed at the age of 10–25. The presence of AA in pregnant women has been raising scientific interest for many years [5–11]. To date, however, only few cases have been reported worldwide. This case report can contribute to the development of management standards in cases of pregnant patients with aplastic anemia. The management of such patients requires close cooperation between obstetrician-gynecologists and hematologists. In spite of the fact that the disease carries a significant risk for pregnant patients, recent years have shown an improvement in the prognosis which is associated with improved symptomatic treatment.

## CASE REPORT

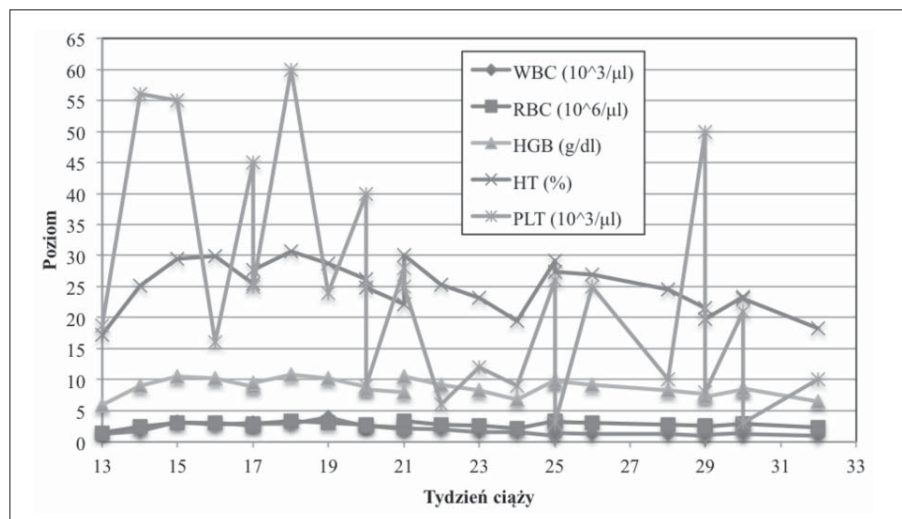
The patient aged 29, 14 weeks pregnant, was admitted to the Clinic of Hematology of the Medical University of Łódź, Poland, due to profound pancytopenia. She had not received treatment due to chronic diseases before or taken drugs of myelotoxic properties. Prior to conception, the patient used clomifene for 6 months in order to stimulate ovaries due to primary infertility lasting for 6 years. Upon admission, complete blood count (CBC) revealed considerably decreased counts of leukocytes ( $1.42 \times 10^3/\mu\text{l}$ ), granulocytes ( $0.96 \times 10^3/\mu\text{l}$ ), erythrocytes ( $1.3 \times 10^6/\mu\text{l}$ ) and platelets ( $16 \times 10^3/\mu\text{l}$ ). The level of hemoglobin was 5.3 g/dl. Complete blood count before pregnancy was normal. The levels of iron, folate and vitamin B12 were normal. Hepatitis B, C and HIV infection were ruled out. Bone marrow trepanobiopsy performed in the 14th week of gestation revealed cellularity of 20% and aplasia of all 3 hematopoietic cell lines without bone marrow alien cells. It was decided to implement symptomatic treatment, and a low dose of steroids was used (20 mg of prednisone). Due to the lack of improvement after a month of treatment, cyclosporine A was added at a starting dose of 5 mg/kg with the monitoring of its serum concentration. In the initial stage of pregnancy, the patient was in a good general condition. Apart from paleness of the skin and mucous membranes, no other anemia- or thrombocytopenia-related signs were observed. At the end of gestation, the patient presented poorly intensified signs of thrombocytopenia: petechiae and spontaneous bruises. Throughout the entire pregnancy, the patient required regular blood product transfusions: initially packed red blood cells (PRBCs) every 2 weeks, and later, due to greater hemorrhagic diathesis, platelet concentrate (PC) every 7–10 days. Fluctuations of CBC are presented in Fig. 1.

More intensified neutropenia (Fig. 2) was observed, but there were no severe infections. The patient need-

ed no infection prevention. At week 28 of gestation, a complete diagnostic process of TORCH and parvovirus infection was conducted but no intrauterine infection was found. Neutropenia that persisted throughout the pregnancy had no influence on the frequency of infections compared with normal pregnancy. During the entire period of observation, the patient developed one upper respiratory tract infection of a mild course, which was controlled with oral amoxicillin. Because of deposits on the mucous membranes in the oral cavity, a nystatin suspension was also used. At weeks 21 and 33, the patient developed oral herpes which was treated with acyclovir. The patient used prednisone, cyclosporine A, potassium chloride and intravenous preparation of chlorquinaldol and metronidazole throughout the entire pregnancy.

Up to week 33, the course of pregnancy was uncomplicated. The patient was hospitalized three times at the Clinic of Perinatology for fetal observation and infection screening at weeks 21 and 28. At week 33, the patient was admitted with outflowing clear amniotic fluid (every 4 hours). Upon admission to the delivery room, the initial contractile activity was observed (every 6–7 minutes). A pelvic examination revealed the vagina with the length of 1 cm and cervical dilatation of 2 cm. The presenting part of the fetus was the head. An ultrasound examination revealed no amniotic fluid and estimated the fetal weight at 1,850 g. The flow waveform in the umbilical artery was normal. Test findings at admission were as follows: WBC= $0.9 \times 10^3/\mu\text{l}$ , RBC= $2.9 \times 10^6/\mu\text{l}$ , Hb=8.5 g/dl, HCT=23%, PLT= $6 \times 10^3/\mu\text{l}$ . 6 units of PRBCs and 6 units of PC as well as uterotonic agents (Pabal, Enzaprost and Oxytocin) were secured. The surgical ward was informed to be prepared for possible iliac artery ligation. The patient's attending hematologist was consulted. It was decided to start a steroid therapy (12 mg of betamethasone), and the use of recombinant granulocyte colony stimulating factor (G-CSF) was planned.

**Fig. 1.** Complete blood count values during pregnancy



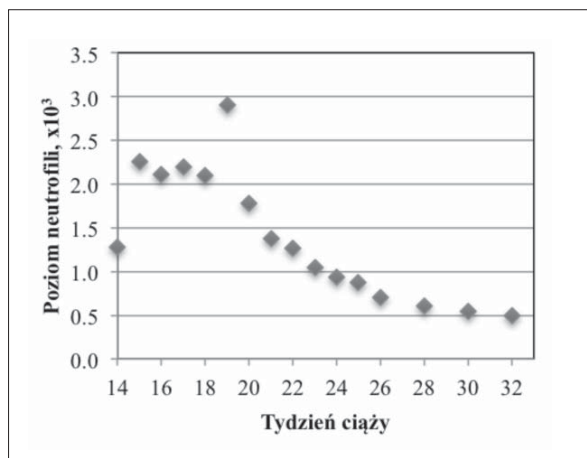


Fig. 2. Neutrophil count values during pregnancy

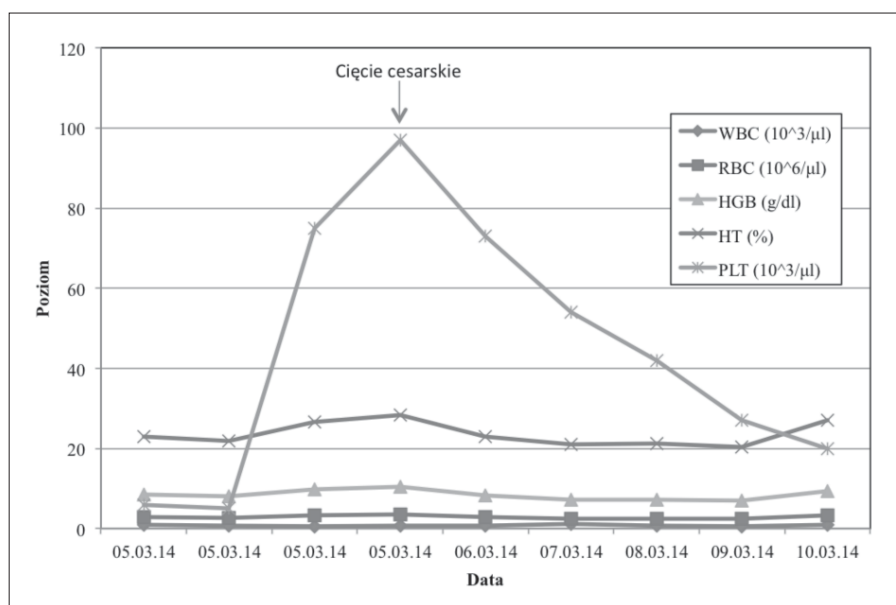
Following initial transfusion of 2 PRBC units and implementation of broad-spectrum antibiotic therapy (ampicillin and erythromycin), the management plan was designed: platelet concentration transfusion and conducting natural labor without epidural anesthesia due to a low platelet count. Following the transfusion of 10 units of PC, the level of  $75 \times 10^3/\mu\text{l}$  was obtained after a few hours. Because the labor did not progress despite amniotic fluid outflow for 12 hours, the patient was adequately prepped (platelet level ensuring hemostasis) and sent for a cesarean section. The procedure was performed under general endotracheal anesthesia. The patient delivered a son with the body weight of 1,750 g and 8/8 points in the Apgar scale. No increased bleeding or other abnormalities were detected during the procedure. Uterine contraction was obtained with carbetocin and enzaprost, administered prophylactically. Uterine curettage was performed. In the post-partum

period, isolation and wide-spectrum antibiotic therapy with cephalosporin and aminoglycoside were used. Because of increased risk of infection due to injury during breast feeding and planned hematologic treatment, lactation was inhibited. A G-CSF product (Filgastrim 48 million units) was used with CBC monitoring, as recommended by the attending hematologist. 2 units of PRBCs were transfused on day 4 after surgery. CBC values during labor and post-partum period are presented in Fig. 3.

The patient was discharged from the obstetric unit on day 5 after the cesarean section in a good general condition and with recommendations to continue treatment in the Clinic of Hematology. Her CBC was as follows:  $\text{WBC} = 1.0 \times 10^3/\mu\text{l}$ ,  $\text{RBC} = 3.38 \times 10^6/\mu\text{l}$ ,  $\text{Hb} = 9.4 \text{ g/dl}$ ,  $\text{HCT} = 27\%$ ,  $\text{PLT} = 20 \times 10^3/\mu\text{l}$ .

After the conclusion of pregnancy, complete blood count parameters did not improve and the patient still depended on blood product transfusions. More intense vaginal bleeding was observed in the later stages of the post-partum period. On day 20 and 24 of the post-partum period, the patient reported to the regional hospital due to vaginal bleeding. Following uterine curettage, she was referred to a tertiary obstetric center where it was deemed necessary to immediately transfuse platelet and red blood cell products ( $\text{Hb} = 6.5 \text{ g/dl}$ ,  $\text{PLT} = 19 \times 10^3/\mu\text{l}$ ) in a hematology unit. Bleeding decreased following PC transfusion. Because there was no family donor, a decision was made to use immunosuppression following the post-partum period. The patient received antithymocyte globulin (ATG) and cyclosporine A. Currently, CBC is regenerating after treatment. The patient still requires periodic blood product transfusions. However, granulocyte count has been observed to return to normal levels. The immunosuppression treatment is planned to be assessed after 6 months of its implementation.

Fig. 3. Complete blood count values during delivery and first days of postpartum period



## DISCUSSION

Aplastic anemia is a rare disease that carries a serious prognosis when no adequate treatment is implemented [1–4]. The history in acquired AA is short – usually several weeks. The clinical picture may show bleeding diathesis associated with thrombocytopenia. This usually involves the tendency to bleeding from the mucous membranes: from the nose, gums, gastrointestinal tract, vagina or urinary tract. Moreover, bleeding to the central nervous system can also occur. Skin defects are typical: petechiae and spontaneous bruises. Patients frequently develop atypical infections associated with profound neutropenia. Tonsillitis with necrotic, ulcerative or aphthous lesions is typical. Another characteristic feature is no response to empirical antibiotic therapy. AA patients demonstrate higher incidence of severe bacterial and fungal infections. Patients can also present with symptoms associated with profound anemia, such as weakening, poor tolerance of physical exercise and dyspnea on exertion. These symptoms, however, were not observed in the patient presented above [6–7].

Complete blood count usually demonstrates pancytopenia. Peripheral blood smear reveals, frequently profound, neutropenia. The percentage of reticulocytes is decreased or normal. A histological examination of the bone marrow is an essential part of the diagnostic process. It usually shows decreased cellularity, hypoplasia or aplasia of hematopoietic cells. The aim of such a histological analysis is also the exclusion of other diseases with concomitant pancytopenia, such as myelodysplastic syndrome or acute leukemia. There are three types of AA: mild, severe and very severe [1–3] (Tab. 1). The patient presented above was diagnosed with severe aplastic anemia.

The prognosis in patients who receive only symptomatic treatment depends on the severity of cytopenia in the peripheral blood. Owing to favorable prognosis, patients with mild AA are usually treated symptomatically. Those with severe and very severe forms should receive causal treatment [13–15]. In young patients who have a HLA matching family donor, allogeneic hematopoietic stem cell transplantation is the treatment of choice. Older patients and those without a family donor of the bone marrow are treated with immunosuppression [13–15].

The potential AA induction by pregnancy has been a subject of debate for many years. The first case of AA

reported in the medical literature (Ehrlich, 1888) was a pregnant patient [5]. The current knowledge about AA in pregnant women is based on case reports or experience of single centers [6–11]. The course of the disease in these women varies. In some patients, spontaneous hematologic improvement is observed after delivery. In women treated with immunosuppression due to AA, its recurrence during pregnancy is likely. Snyder et al. proposed criteria for aplastic anemia in pregnant patients, which include: diagnosis during pregnancy, no factors that could cause toxic bone marrow injury, pancytopenia in peripheral blood and hypoplasia of the bone marrow in trepanobiopsy [11]. These criteria were met in the case reported above.

Improved prognosis in pregnant AA patients is associated with greater efficacy of symptomatic treatment. However, there are no uniform guidelines concerning the management in pregnant patients. First of all, adequate treatment of infection in patients with neutropenia must be instituted. In this case, intensive intravenous broad-spectrum antibiotic therapy is used in combination with antifungal and antiviral agents. Severe infections in AA patients are also managed with recombinant G-CSF products. They enable granulocyte levels to be transiently increased, which is essential to control infection. AA patients demonstrate a high level of endogenous erythropoietin (EPO). That is why the usage of its recombinant preparations is groundless [3]. Another element of symptomatic treatment is transfusion of leukocyte-poor and irradiated blood products, i.e. packed red blood cells and platelet concentrates. In the patient presented above, a total of 15 PRBC units were transfused, and 5 units of PC were given 20 times (1 standard platelet concentrate contains 5 units) before labor. On the day of a cesarean section, 2 units of PRBCs and 2 PCs were transfused. On day 4 of the post-partum period, additional 2 units of PRBCs were used.

Kwon et al. reported 14 cases of pregnancy-associated AA in one center [8]. Symptomatic treatment involved blood product transfusion so as to maintain Hb above 8 g/dl and PLT above  $20 \times 10^3/\mu\text{l}$ . The mortality rate among treated mothers was 0%. It can be therefore assumed that the aforementioned platelet and hemoglobin values are a safe minimum. The prognosis in patients who are treated only symptomatically during pregnancy is good. During the preparation for delivery, a platelet concentrate must be transfused to ensure PLT level

**Tab. 1.** Diagnostic criteria of severe and very severe AA

	Severe AA	Very severe AA
Bone marrow cellularity	Below 25%	As in the severe form
<b>At least 2 of the 3 following criteria:</b>		
Neutrocytes	Below $0.5 \times 10^9/l$	Below $0.2 \times 10^9/l$
Platelets	Below $20 \times 10^9/l$	As in the severe form
Reticulocytes	Below $60 \times 10^9/l$	As in the severe form

of  $>50 \times 10^3/\mu\text{l}$  when natural delivery is planned and  $>80 \times 10^3/\mu\text{l}$  in the case of a cesarean section. Epidural anesthesia can be administered when PLT count is  $100 \times 10^3/\mu\text{l}$  [12].

In the case presented above, the maximum level of thrombocytes obtained on the day of delivery, after two transfusions of platelet concentrate, was  $76 \times 10^3/\mu\text{l}$ , which enabled a safe cesarean section to be performed. When deciding about the optimal manner of concluding pregnancy, obstetric indications should be taken into account in the first place. Due to the use of cyclosporine, breast-feeding in the post-partum period is not possible. Bromocriptine was used in the case presented.

Some patients require the initiation of causal AA treatment during pregnancy. However, intensive treatment cannot be executed safely in the pregnant. The administration of antithymocyte globulin and allogeneic bone marrow transplantation carry a too high risk of complications. The data obtained while observing pa-

tients after kidney transplantation indicate that the use of cyclosporine A during pregnancy is safe for the fetus. Pregnant AA patients, in whom causal treatment is indicated, are recommended to use cyclosporine A orally at a starting dose of 5 mg/kg daily with dosage modification to obtain drug concentration in the serum at a level of 150–250  $\mu\text{g/l}$ . Moreover, the usage of low-dose corticosteroids can be considered.

## CONCLUSION

Interdisciplinary approach and close cooperation between obstetricians and hematologists in the management of a severely ill pregnant woman have contributed to the success in the form of a child delivery and a possibility of implementing treatment proper for the hematologic disease that developed during pregnancy. There are no recommendations concerning the treatment of aplastic anemia. Proper management of pregnant patients with this disease is possible only thanks to case reports and clinical experience of specialist centers.

## References:

1. **Marsh JCW, Ball SE, Darbyshire P et al.** Guidelines for the diagnosis and management of acquired aplastic anaemia. *Br J Haematol.* 2003;123:782.
2. **Marsh JC, Ball SE, Cavenagh J et al.** Guidelines for the diagnosis and management of aplastic anaemia. *Br J Haematol.* 2009;147: 43–70.
3. **Guinano EC.** Diagnosis and management of aplastic anaemia. *ASH Educational Book.* 2011;76-83.
4. **Brodsky RA, Jones R.** Aplastic anaemia. *Lancet.* 2005;365:1647-1656.
5. **Ehrlich P.** Über einen fall von Anämie, mit Bemerkungen über regenerative veränderungen des knochenmarks (A case of anemia combined with change of bone marrow finding) *Charite Ann.* 1888; 13:300-309.
6. **Choudhry VP, Gupta S, Gupta M et al.** Pregnancy associated aplastic anemia – a series of 10 cases with review of literature. *Hematology.* 2002;7:233-238.
7. **Tichelli A, Socie G, Marsh JC et al.** Outcome of pregnancy and disease course among women with aplastic anemia treated with immunosuppression. *Ann Intern Med.* 2002;137:164-172.
8. **Kwon JY, Lee Y, Shin JC et al.** Supportive management of pregnancy-associated aplastic anemia. *Int J Gynaecol Obstet.* 2006; 95:115-120.
9. **Stibbe KJ, Wildschut HI, Lugtenburg PJ.** Management of aplastic anemia in a woman during pregnancy: a case report. *J Med Case Rep.* 2011;15:5-66.
10. **Deka D, Banerjee N, Roy KK et al.** Aplastic anaemia during pregnancy: variable clinical course and outcome. *Eur J Obstet Gynecol Reprod Biol.* 2001;94:152-154.
11. **Snyder TE, Lee LP, Lynch S.** Pregnancy-associated hypoplastic anemia: a review. *Obstet Gynecol Surv.* 1991; 46(5):264-269.
12. **Mezner-Zawadzka E, Kruszyński Z, Gaca M.** Analgezja zewnątrzoponowa porodu – wytyczne. *Anest Intens Ter.* 2009;41:114-118.
13. **Scheinberg P.** Aplastic anemia: therapeutic updates in immunosuppression and transplantation. *ASH Educational Book.* 2012; 292-299.
14. **Scheinberg P, Young NS.** How I treat acquired aplastic anemia. *Blood.* 2012; 120:1185-1196.
15. **Scheinberg P, Nunez O, Weinstein B et al.** Horse versus rabbit antithymocyte globulin in acquired aplastic anemia. *N Engl J Med.* 2011;365:430-438.